

Original Research Article

Surgical treatment of tibial pilon fractures : About 54 cases

ABSTRACT:

The Study carried out a retrospective study of a series of 32 cases of tibial pilon fractures, treated surgically in the traumatology-orthopedics department of the IBN EL JAZZAR Hospital in KAIROUAN, over a period of 8 years from January 2014. to December 2021.

The fracture of the tibial pilon affects young active subjects, with an average age of 42 years, and a male predominance, the sex ratio M/F equal to 2.2. The etiological circumstances were dominated by high-energy trauma: (The common causes of high energy trauma were): falls of a high place at 47%, (fall from height) followed by public road accidents at 31.25%. Standard front (Anteroposterior view) and lateral x-rays of the ankle made it possible (statement is wrong, we use ankle series to confirm the diagnosis; AP, Lateral and Mortise view) to confirm the diagnosis, and to analyze the different anatomopathological (morphology) types of the fracture. Surgical treatment by open osteosynthesis was carried out in 65% of cases; combined treatment in 24% of cases (combined treatment means ?); and closed treatment in 11% of cases. According to SOFCOT clinical criteria, functional results were good in 65% of cases, average in 25% of cases, and poor in 10% of cases. The analysis of our results showed a majority of good clinical and radiological functional results with open treatment: which showed its superiority compared to closed treatment; and combined treatment. Complications noted were infection; skin necrosis; algodystrophy.

Keywords: tibial pestle-osteosynthesis

I. INTRODUCTION

Fractures of the tibial pilon represent 3 to 10% of all tibial fractures. They arise from high-energy trauma by axial compression. They are serious given: their complexities, their therapeutic difficulties and the absence of muscular coverage with vascularization, making the prognosis severe dominated by the risk of skin necrosis, infection, malunion, pseudarthrosis and osteoarthritis [1]. (You need to correct your sentences and write a clear message of what you are trying to convey)

The development of anatomical implants with angular stability and the recent improvement in the definition of surgical approaches have clearly changed the prognosis of these lesions. (fractures)

II. MATERIALS AND METHODS

This is a retrospective study, however, on 32 cases of tibial pilon fractures treated surgically, within the orthopedic traumatology department of the IBN EL JAZZAR Hospital in KAIROUAN over a period of 8 years, from January 1, 2014 to December 31 2021,

Through 450 ankle traumas collected at the orthopedic traumatology department of the IBN EL JAZZAR Hospital in KAIROUAN over the same study period, we noted a number of 54 fractures of the tibial pilon, or 12% of ankle fractures. The population most exposed in our study was the young and active population. With an average age of 37 for men, and 41

for women. with a clear male predominance with 22 men or 68% and 10 women or 32% with a sex ratio of 2.2. The left side was affected in 60%. Concerning the etiologies we noted: Falls from a high place in 46.87%, AVP came second with a percentage of 31.25%, Sports accidents were less frequent than in 15.62%. Assaults in only 6.25% of cases.

In our study, we noted a clear predominance of the indirect mechanism (59%) in the occurrence of tibial pilon fractures.

UNDER PEER REVIEW

Clinically, we grouped 14 open fractures, or 22%; including 7 type I cases, 5 cases classified as type II, and 2 cases classified as type III.

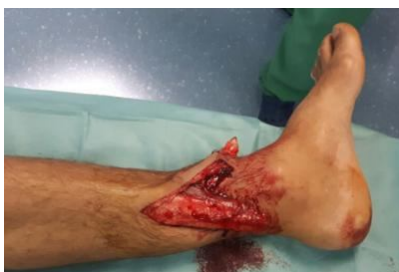

Figure 1: clinical image showing an open fracture of the left tibial pilon.

The assessment includes standard x-ray images of the ankle in frontal and lateral view, centered on the ankle. The profile must include the entire rearfoot and calcaneus. These two images make it possible to diagnose bone lesions according to the SOFCOT classification [2].

In our study, all our patients systematically benefit from CT imaging.

In our study, due to their therapeutic and prognostic implication, bone lesions were analyzed and listed according to the SOFCOT classification [3].

| Type of fracture | | Effective | Percentage |
|--|-------------------------------|-----------|------------|
| Marginal anterior | with acute articular trait | 5 | 9.375% |
| | with multiple articular lines | 2 | 3.125% |
| Posterior marginal | | 2 | 3.125% |
| Sagittal | | 2 | 3.125% |
| Sipiroid of the tibia irradiated to the tibial pilon | | 24 | 43.75% |

Table 1: Distribution of incomplete fractures

According to the SOFCOT [3] classification of tibial pilon fractures, in our study, we noted the predominance of complete articular fractures in 32 cases or 59,375% (?) then incomplete fractures come in 22 fractures or 40,625% (?) of cases.

| Type of fracture | Percentage |
|---------------------|------------|
| Complete fracture | 59.38% |
| Incomplete fracture | 40.63% |

Table 2: Distribution of tibial pilon fractures according to the SOFCOT classification

Depending on the intensity of the trauma and the point of impact, talocrural dislocation or subluxation is often associated with tibial pilon fractures.

In our study, 7 patients presented with a tibial-talar dislocation, i.e. 12.5% of cases.

17 patients presented with osteochondral depression.

Therapeutically All our patients benefited from surgical treatment:

Approaches first:

| | | |
|-------------------------------------|----|---------|
| Anterolateral | 4 | 6.25% |
| Previous | 2 | 3.125% |
| Medial | 29 | 56.25% |
| Lateral for fibula | 2 | 3.125% |
| Double approach (internal/external) | 12 | 21.875% |

Table 3: Distribution according to the approaches used

In our series, the internal approach was more frequently used in 18 cases or 56.25%, then the double approach (internal/external) with a rate of 21.875%. (what do you mean by double approach ?is it combination of double incision approach ? why you wrote internal or external ?

Distribution of therapeutic fixation modalities:

a. Internal fixation:

The osteosynthesis was carried out by:?????

UNDER PEER REVIEW

| Technical terms | | Number of cases | Percentage | |
|-----------------|--------------------------|---------------------|------------|--------|
| Target plate | Isolated | 36 | 68.75% | |
| | Associate | Epiphyseal screwing | 5 | 9.375% |
| | | Epiphyseal pinning | 2 | 3.125% |
| Screwing | Simple | 7 | 12.5% | |
| | Associated with a pinout | 4 | 6.25% | |

Table 4: Distribution according to therapeutic modalities

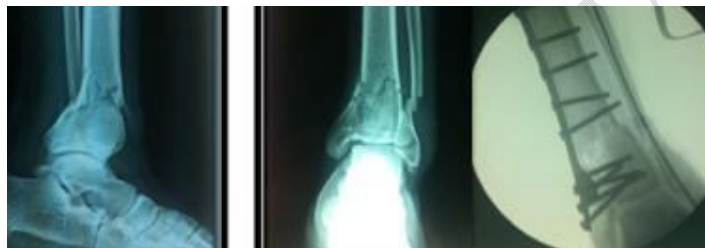

Figure 2: X-ray of the ankle face and profile showing (Ankle AP and lateral) a complex fracture of the tibial pilon treated with a trefoil plate with pinning of the fibula.

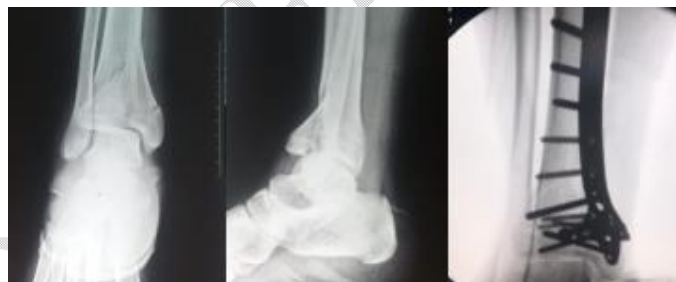

Figure 3: x-ray of the ankle front and profile showing a complex fracture of the tibial pilon treated with a trefoil plate.

b. External fixation:

In our study, the external fixator was used in 4 cases.

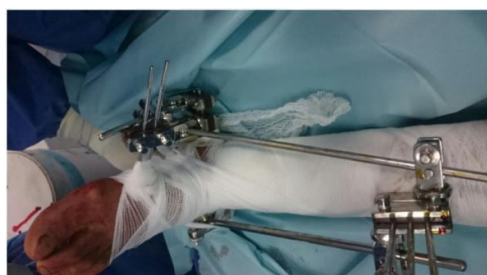

Figure 4: clinical image showing a Hoffman external fixator assembly.

Postoperative complications:

In our series, 7 patients presented complications, or 12.5% of cases.

- Infection was noted in 4 patients

- Skin necrosis was seen in 3 cases:

2 cases limited to one centimeter not exposing the osteosynthesis material in which the evolution was good.

1 case exceeded one centimeter and exposed the osteosynthesis material, which was treated with a fasciocutaneous rotation flap.

III. RESULTS

The patients were reviewed with a mean follow-up of 2 years and 3 months with extremes of 10 months and 4 years. The results were assessed, according to the SOFCOT 1991 score [2]

UNDER PEER REVIEW

They were obtained according to the clinical evaluation criteria defined by Biga Sofcot [2] which we adapted to the fractures in our study, without taking into account the type of treatment.

| Results | Percentage |
|-----------|------------|
| Excellent | 21% |
| Good | 38% |
| AVERAGE | 24% |
| Bad | 17% |

Table 5: Results according to BigaSofcot criteria

a. Functional results depending on therapeutic modalities:

The results were excellent and good in:

60% of patients treated with internal osteosynthesis.

30% of patients treated by external osteosynthesis.

10% of patients treated with combined treatment.

b. Radiological results:

The criteria described by Arlettaz [4] allowed us to collect our results; In our study, the results are as follows:

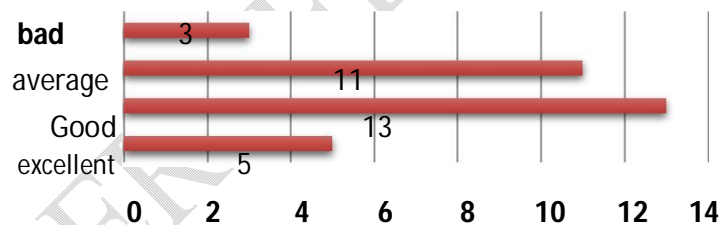


Figure 5: The quality of radiological reduction in our patients (You need to modify your graph)

IV. DISCUSSION

The use of the term "Pilon Tibial" comes from Etienne DESTOT in 1911 in his work on radiological description of foot fractures [5]. The term Pilon came about through the resemblance of the shape of the distal tibia to a drumstick.

According to BourneArlettaz and Evan [4,6,7] they represent 7% of tibia fractures and 1% of lower limb fractures. Decoulx, Razemon, Rousselle [10] grouped 13.7% of tibial pilon fractures out of 350 cases of instep fractures.

In these different series [4, 8, 9], the average age varies between 38 and 45 years. In our study, the age group between 40-49 years old is the most exposed; Which corresponds to the active population, as well as the predominance of accidents on public roads.

In our series we observe a clear male predominance with 68% men for 32% of women ; i.e. a sex ratio of 2.2 men/1 woman (2.2 vs 1). Which is consistent with the literature [4, 11, 12,13, 14].

Male exposure to violent trauma is linked to professional activity and

Most cases of fracture in our study result from a high-energy injury mechanism. The etiologies were dominated by: a fall from a high place, public road accidents and road accidents **sport**. This remark is consistent with that of several authors [15, 16].

Skin lesions associated with this fracture are considered an important early and secondary risk factor, following the precarious cutaneous vascularization of this region. **In our series, fractures closed are the most frequent, and it is the same in the literature** [17, 18, 19, 20]. Closed fractures were most frequent in our study which was same as in previous studies.

| Authors | Closed fractures (%) | Open fractures (%) |
|------------|----------------------|--------------------|
| Leung [17] | 81 | 19 |
| Bacon[18] | 54 | 46 |
| Babis[19] | 72 | 28 |
| Manca[20] | 73 | 27 |
| Our study | 80 | 20 |

Table6: Distribution of cases according to skin opening

Radiologically; the frontal and lateral views centered on the **tibioastragal** space are sufficient to make the diagnosis of tibial pilon fracture and obtain an anatomic-radiological classification.

Other complementary incidences may prove useful such as the frontal incidence in external rotation at 10° of the foot which better clears the ceiling of the mortise and the tibio-talar space, as well as the 3/4 incidence which allows us to identify the superposition of the fracture lines with the fibula.

Computed tomography is of interest for the evaluation and classification of fractures which are difficult to study using standard radiography, as well as for the preoperative planning of surgical treatment [21,22]. It makes it possible to choose the approach to adopt, through the measurement of the fracture angle formed by the **axetibio-fibular** and the majority fracture line:

The incision must be lateral if the fracture angle is < 90°.

The incision must be antero-internal, if the fracture angle is >90°.

The use of MRI is reserved for the evaluation of ligamentous and other soft tissue injuries, which are often associated with malleolar fractures [23].

Numerous classification systems have been developed since the 1960s[2].

At the end of the 1960s, the classification of Rüedi and Allgöwer was the most recognized internationally for these lesions [24,25].

A new classification was developed at the 1991 symposium of the French Society of Orthopedic Surgery and Traumatology (SOFOT) for tibial pilon fractures [3], based on the work of Vives and Hourlier; as well as the analysis of Gay and Evrard.

In our series, we adopted the latter, because it allowed us to conclude the rate: fractures with incomplete metaphyseal rupture including 40.5% and fractures with complete metaphyseal rupture including 59.5%.

According to the literature, whatever the classification used: the rate of fractures with complete metaphyseal rupture is higher than that of fractures with incomplete metaphyseal rupture [4,26].

The management of tibial pilon fractures must be an immediate emergency, otherwise it is a delayed emergency following several reasons:

Post-traumatic edema which causes the skin to suffer;

The importance of comminution;

The poor condition of the soft parts due to skin damage or even to an opening by the large fracture displacement.

The operating time should not exceed 8 to 12 hours; otherwise, it is preferable to postpone the operation 7 to 10 days later while waiting for improvement in the skin condition [27].

Concerning the approach; It is necessary to remember that there is no muscular insertion on the tibial pilon as on the talus, which makes its vascularization fragile. Some basic notions in the choice of surgical approach [28]:

Center the incision on the largest or most displaced fragment, because its exact reduction conditions the entire epiphyseal reconstruction

Avoid traumatizing the skin with aggressive retractors, it is therefore necessary to make large incisions allowing good exposure

Respect a minimum distance of 6cm between two vertical

incisions Arthrotomy is essential to monitor the cartilaginous surfaces

the anteromedial route is the most used in our training with a rate of 58%. This route has been adopted by several authors such as: HEIM [29], ARLETTAZ [4] and HELFET [8] followed by the anterolateral route with a rate of 33%.

The most commonly used internal osteosynthesis material is the cloverleaf or anatomical plate. Other plates can be used such as: the thin 'T' plate, L plate, posterior console plate particularly in partial fractures or isolated compressive screwing.

Nailing is limited to type 43A and C1 fractures according to AO classification. It should also be noted that fractures containing a displaced split of the anterior margin of the tibia are excluded from treatment by nailing. Skin closure is the most important part of the procedure, because it is essential to avoid any tension and perfectly suture vital skin.

According to Leone [30], to close the operating wound; it is necessary to start first with the tibial route, then the fibular route for two reasons:

1. Cover the tibial osteosynthesis material.
2. Avoid the occurrence of secondary skin necrosis: since the skin at this stage is thin, fragile and poorly vascularized.

Other authors say that:

- if the two operating wounds are well bleeding and possible to be closed without tension, we will consider the primary closure of the 2 routes

UNDER PEER REVIEW

- if there are skin lesions with a questionable vascular state of the surgical wounds: the tibial approach must first be closed, then the subcutaneous tissue should be brought closer to the peroneal approach, leaving the skin for directed healing [31].

In our study, the external fixator was used in 25% of cases for complex fractures where the skin condition and the type of fracture did not allow the use of internal osteosynthesis or traction. According to Babis

[19], external fixation presents less risk of complications.

The objective of minimally invasive surgery is: the reduction and stabilization of the fracture site with a result approximately equivalent to that obtained with the approach to the fracture site; while reducing surgical aggression. This technique is aimed at minimally displaced fractures; without jointnmetaphyseal comminution.

Arthrodesis also finds its place in fractures with significant joint damage and the association with cartilaginous lesions of the talus makes any reconstruction impossible. Furthermore, there is never an emergency to carry out an arthrodesis, if the indication is made; this can be carried out remotely in better conditions in the absence of soft tissue pain.

The risk of secondary complications is present, as with any surgery, of which infection comes first. It can be increased due to the fact that the skin of the leg is fragile, the bone is under the skin.

These complications have an impact on short- and long-term functional results.

V. Conclusion :

In the light of our retrospective study, which focused on a series of 54 cases treated surgically, we note the seriousness of these fractures, as long as they affect the long-term functional prognosis; and still remain a real challenge for the surgeon.

Consent :

Written informed consent was obtained from the patients for publication and any accompanying images. A copy of the written consent is available for review by the Editor-in-Chief of this journal on request.

REFERENCES :

- [1]. MAUFFREY C, VASARIO G, BATTISTON B, LEWIS C, BEAZLEY J, SELIGSON D. Tibial pilon fractures: a review of incidence, diagnosis, treatment, and complications. *Acta OrthopBelg* 2011; 77:432–440.
- [2]. Copin G, Nerot C. Fractures of the tibial pilon in adults (SOFCOT Symposium. Paris, November 1991). *Rev ChirOrthop* 1992; 78 (suppl I):33-83.
- [3]. Nerot C, Tozzini JP. Recent fractures of the tibial pilon in adults. Update of anatomoradiological data and presentation of the series. Classification of tibial pilon fractures. *Rev ChirOrthop* 1992; 78 (suppl I):36 -45.
- [4]. ARLETTAZ Y, BLANC CH, CHEVALLEY F. Fractures of the tibial pilon. Long-term retrospective study of 51 fractures treated by bloody reduction and osteosynthesis. *Rev ChirOrthop* 1998; 84:180-188.
- [5]. Destot E. Foot trauma and X-rays. Masson; 1911.
- [6]. BOURNE R B. Pilon fractures of the distal tibia. *Clin Orthop* 1989;240:42-46.
- [7]. FVANH KARAS I ONS WFINER Dislaced nilon fractures

- [8]. BORRELLI J Jr, ELLIS E. Pilon fractures: assessment and treatment. *Orthop Clin North Am.* 2002 Jan; 33(1):231 -45
- [9]. BIGA N, LAURENT M, ALAIN J, THOMINE JM Prognostic factors, scalability, radio-clinical correlation and tolerance of malunions. *Rev ChirOrthop1992;suppl I, 78.SOFCOT, 66 annual meeting*
- [10]. ALEXANDRE AND L MATHIEU. Assessment and classification of fractures of the tibial pilon; ROC Ecole du val-de-Grace September 25, 2010 RV. Wednesday January 12, 2011.
- [11]. Nicandri GT, Dunbar RP, Wahl CJ. Are evidence-based protocols which identify vascular injury associated with knee dislocation underutilized? *Knee Surg Sports TraumatolArthrosc2010;18:1005–1012.*
- [12]. HELFET D, KENNET K, PAPPAS J. Intra-articular pilon fractures of the tibia. *Clin Orthop Related Research 1994; 298:221-228.*
- [13]. KAO KF, HUANG PL, CHEN YW, LIN SY, KO SH. Postero-medio-anterior approach of the ankle for the pilon fracture. *Injustice2000; 31:71-4.*
- [14]. M.ARZAZ Fracture of the tibial pilon, experience of the orthopedic traumatology service, concerning 25 cases at the MOULAY SMAIL hospital in MEKNES. *Med Thesis Rabat 2005 No. 185.*
- [15]. McCann PA, Jackson M, Mitchell ST, Atkins RM. Complications of definitive openreduction and internal fixation of pilon fractures of the distal tibia. *Int Orthop2011;35:413–8.*
- [16]. Liporace FA, Yoon RS. Decisions and staging leading to definitive open management of pilon fractures: where we come from and where are we now? *J Orthop Trauma 2012;26:488-98.*
- [17]. LEUNG F, KWOK HY, PUN ST, CHOW SP. Limited open reduction and Ilizarov external fixation in the treatment of distaltibial fractures. *Injury2004; 35(3):278-83.*
- [18]. Bacon S, Smith WR, Morgan SJ, Hasenboehler E, Philips G, Williams A, et al. A retrospective analysis of comminuted intra - articular fractures of the tibial ceiling: open reduction and internal fixation versus external Ilizarov fixation. *Injury 2008; 39:196–202.*
- [19]. GCBabis,P.Kontovazenitis,DSEvangelopoulos,P.Tsailas,K.Nikolopoilos,PN;Soucacos; Distal tibial fractures treated with hybrid external fixation, *Injury,Int.J.Care Injured;2010 (41) 253-258.*
- [20]. MANCA M, MARCHETTI S, RESTUCCIA J, FALDINI A,FALDINI C,GIANNINI S. Combined percutaneous internal and external fixation of type C tibial ceiling fractures. *J Bone Joint Surg Am;2003 May; 85 -A (5): 912.*
- [21]. BIGA N, LAURENT M, ALAIN J, THOMINE JM Prognostic factors, scalability, radio-clinical correlation and tolerance of malunions. *Rev ChirOrthop1992;suppl I, 78.SOFCOT, 66 annual meeting*
- [22]. COUDERT B,RAPHAEL M. Recent ankle trauma. *EMC, emergency medicine; 2007, 25-200-G-30*
- [23]. OTHMANE BOUYALITENE. Bimalleolar fracture. *Thesis Casablanca 2003, n°126*
- [24]. DECOULX P, RAZEMON JP, ROUSSELLE Y, Pilontibial fractures, *RevChirOrthop 1961;47:563-577.*
- [25]. Ruedi T, Matter P, Allgöwer M. Die intraartikulären Fracturen des distalen Unterschenkendes. *HelvChir Acta 1968; 35:556-82.*
- [26]. BENCHAKROUN M, ISMAEL F, YACOUBI H et al. Fractures of the tibial pilon about 30 cases. *Medicine and Armies 2003; 31(2): 113-120.*
-

-
- [27]. BRUMBACK RJ, WILLIAM C, MC GARVEY. Fractures of tibial ceiling; evolving treatment concepts for the pilon fractures. Orthop. Clin. North Am; 1995, 26, n°2
- [28]. Plaweski.S, Huboud-Peron.A,Faure.C,Merloz.P, Fractures of the tibial pilon. Medical-surgical encyclopedia (Elsevier, Paris), Musculoskeletal system, 14-087-A10, 1999-Podiatry, 1999, 13p.
- [29]. HEIM U. Fractures of the tibial pilon. SOFCOT teaching notebooks 1997; pp. 35 -51.
- [30]. LEONE V, ROBERT R. The management of the soft tissue in pilon fractures. Clin Orthop Related Research 1993; 292:315-320
- [31]. BOUR P, AUBRY P, FIEVE G. Vascularization of the tibial pilon. Therapeutic applications. Rev. Chir. Orthop. 1992 supp I, vol 78. SOFCOT, 66th Annual Meeting.

UNDER PEER REVIEW

UNDER PEER REVIEW